





CASE REPORTS

Floating-Harbor syndrome – case report with literature review

Trifon T. Popov ¹, Natasha Y. Yaneva ²

¹ Medical Faculty, Medical University, Sofia, Bulgaria

² Clinic for Endocrinology, Diabetes and Metabolism, University Children's Hospital,
Medical University of Sofia, Sofia, Bulgaria

ABSTRACT

Introduction and aim. Floating-Harbor syndrome (FHS) is a very rare disease, whose typical characteristics include short stature, facial dysmorphic features and significant speech delay. We aim to present the first reported case of FHS with discordant growth hormone tests and confirmed hypoplasia of the pituitary gland.

Description of the case. We report a case of a boy aged 8 years and 3 months with a height constantly below the 3rd percentile, delayed bone age in comparison to chronological age, typical dysmorphic triangular face and a high-pitched voice. Whole-exome sequencing (WES) detected a heterozygous pathogenic variant in SRCAP gene – a confirmation of the diagnosis Floating-Harbor syndrome (FHS). Recombinant human growth hormone (rhGH) therapy at a dose of 0.033 mg/kg/day (0.65 mg/day) was initiated at the age of 7 years and 10 months. Because of the insufficient growth velocity at the time of manuscript preparation a dose increase was made to 0.035 mg/kg/day (0.80 mg/day).

Conclusion. In children presenting with short stature (especially when GH deficiency is confirmed), facial dysmorphism and developmental delay, Floating-Harbor syndrome should be considered as a possible diagnosis. A multidisciplinary approach involving pediatric endocrinologists, geneticists and developmental specialists is essential for timely etiological diagnosis and optimal management.

Keywords. Floating-Harbor syndrome, recombinant human growth hormone treatment, short stature

Introduction

Floating-Harbor syndrome (FHS) is a rare genetic disorder, with approximately one hundred documented cases in the scientific literature worldwide.¹ This syndrome derives its name from the names of the hospitals in the United States (Boston Floating Hospital and Harbor General Hospital in California), where the first cases were reported (unlike the majority of the genetic diseases that are named after the physicians who initially described them).¹ FHS is attributed mainly to a point mutation (frameshift or nonsense mutation) in the SRCAP gene, which is located on the short arm of 16 chromosome 16p11.2 and encodes the central catalytic

subunit of the SNF2-Related CBP Activator Protein (SRCAP).² This protein is an ATPase that modulates gene expression by chromatin remodeling and interaction with transcription activators (CREBBP/CBP).² Pathogenic variants in SRCAP gene are located in exons 33 or 34 and, in the most cases, arise de novo, although rare examples of autosomal dominant inheritance have been reported in familial cases.³

The clinical phenotype of FHS is the characteristic triad: short stature, severe language developmental delay, as well as typical facial dysmorphologies.¹ Height is persistently below the 3rd percentile and is attributed to the growth hormone (GH) deficiency.¹ Bone age lags

Corresponding author: Trifon T. Popov, e-mail: 102268@students.mu-sofia.bg

Received: 25.09.2025 / Revised: 30.11.2025 / Accepted: 10.12.2025 / Published: 30.03.2026

Popov TT, Yaneva NY. Floating-Harbor syndrome – case report with literature review. *Eur J Clin Exp Med*. 2026;24(1):227–233. doi: 10.15584/ejcem.2026.1.25.



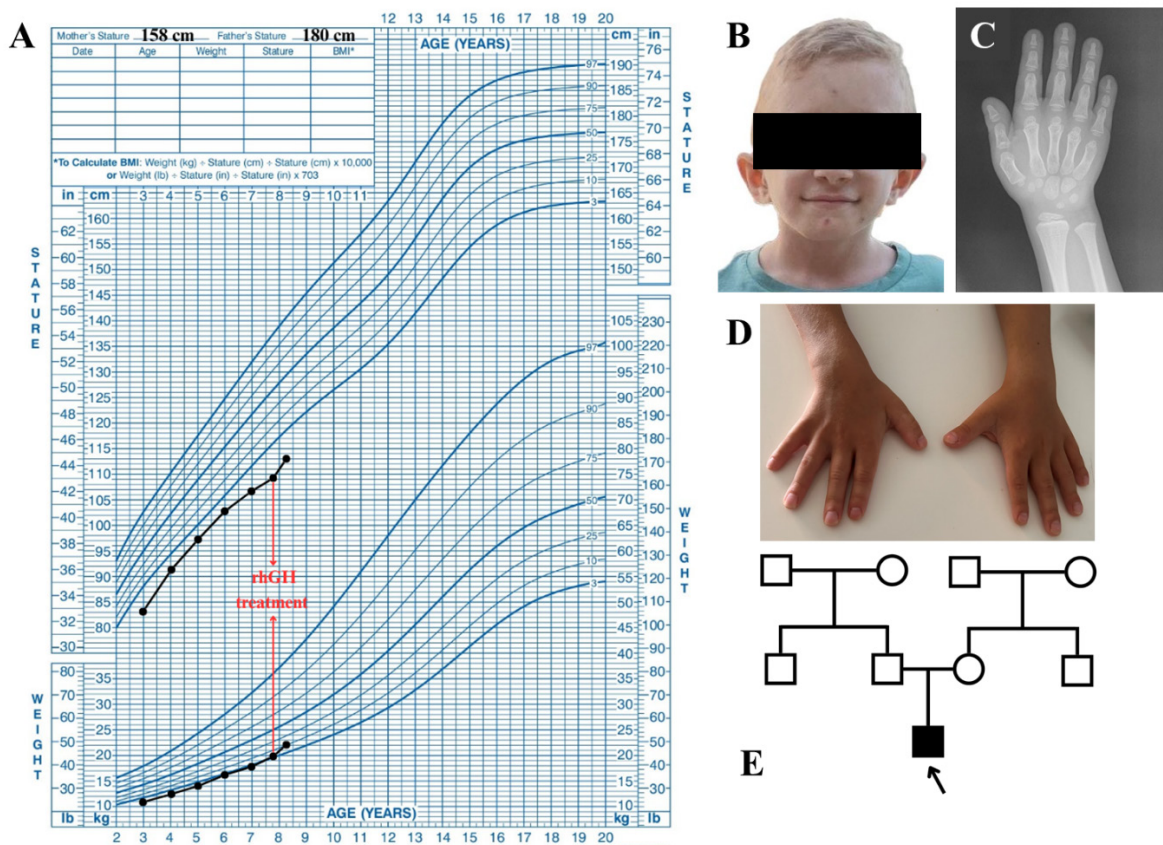


Fig. 1. Characteristics of the patient: A: Growth chart from the age of 3 years to present, B: Triangular dysmorphic face of the child, C: Radiography of the left forearm – a bone age of 4 years and 6 months (2 years and 7 months behind patient's chronological age), D: Small hands with hypertrophy of the distal phalanges of the fingers and prominent nail plates, E: Family tree confirming the de novo emergence of the pathogenic variant

behind chronological age.¹ The typical facial features of FHS patients are a triangular facial shape, deep-set eyes, a prominent nasal bridge with a broad nose and enlarged nostrils, a short philtrum, and a wide mouth with thin upper and lower lips. Some patients may also have dental anomalies, such as delayed eruption of primary and permanent teeth, microdontia and others.¹ While motor development is generally normal, neuro-psychic and language development are delayed. The voice is also specific – screaming (more pronounced during laughing or crying). Skeletal abnormalities – such as brachydactyly, clinodactyly, vertebral anomalies, additional rib, short neck, etc. – can be seen in some patients with FHS.⁴ Another less common clinical manifestations may include cardiac, sensory (hearing, eye), genitourinary, gastrointestinal anomalies.⁴ This rare disease may present with behavioral challenges, including attention-deficit/hyperactivity disorder (ADHD) and learning difficulties.⁴ The diagnosis of Floating-Harbor syndrome is based primarily on clinical evaluation and can be confirmed through molecular genetic analysis, specifically whole exome sequencing (WES) or targeted sequencing of SRCAP gene, which reveals a heterozygous pathogenic variant in exon 33 or 34.^{2,4}

Aim

The purpose of this case report is to describe the first reported case of Floating-Harbor syndrome with discordant GH tests and MRI confirmed pituitary hypoplasia.

Description of the case

The patient is a male aged 8 years and 3 months, born from a first, complicated pregnancy of a mother with type 1 diabetes and Hashimoto's thyroiditis, with inadequate glycemic control during pregnancy and under therapy with L-thyroxin. A course of indomethacin was administered in the 7th lunar month due to polyhydramnios. Delivery occurred at term via cesarean section. The newborn's weight was 4170 g (+1.23 SDS) and length of 56 cm (+2.16 SDS), in asphyxia requiring resuscitation in the delivery room, oxygen therapy, antibiotics and phototherapy. A persistent foramen ovale with left-to-right shunt was established. The patient is regularly immunized.

Since the age of 3 years, the patient has constantly grown below the prognostic stature (175,5 cm, -0.37 SDS), calculated as (mother's height + father's height + 13)/2. As shown on the height and weight growth charts (Fig. 1A), the growth curve lies below the 3rd percent-

tile. At the age of 3 years and 2 months, he was evaluated by a psychologist who reported slightly delayed speech development and coefficient of development 86 (low-normal range) was reported. Due to the dysmorphic features and delays in physical and cognitive development, karyotyping and MLPA testing for microdeletions, subtelomeric deletions, and duplications were performed, with no abnormalities found. At 4 years and 5 months, the patient's height and weight were (-3.07 SDS), his bone age was 2 years and 6 months (delay of 1 year and 11 months from calendar) and the level of insulin-like growth factor-1 (IGF-1) was 118.0 ng/mL (-0.08 SDS). Hypermetropia was identified and corrected with spectacles: right eye +4.5 diopters spherical, left eye +4.5 diopters spherical.

Table 1. Laboratory analyses before and 6 months after rhGH treatment

Parameter	Results before rhGH therapy	Results after rhGH therapy	Units	Reference range
Fasting glucose	4.89	4.76	mmol/L	4.11–5.89
HbA _{1c}	5.27	5.20	%	4.0–5.7
Total cholesterol	4.14	3.79	mmol/L	<5.2
LDL	2.60	2.00	mmol/L	<3.5
HDL	1.19	1.09	mmol/L	>0.9
ASAT	23.0	20.9	U/L	10–46
ALAT	17.0	13.2	U/L	5–37
GGT	15.0	12.0	U/L	5–31
Albumin	45.24	45.3	g/L	32–55
TSH	3.51	3.82	mIU/L	0.58–4.1
ft4	16.7	17.2	pmol/L	9.5–16.5
MAT	<10.0	<10.0	IU/mL	<35.0
TAT	<20.0	<20.0	IU/mL	<40.0
IGF-1	84.8	208.0	ng/mL	40–255

The patient was not followed up until the age of 7th year 1 month, when he was admitted to the Endocrinology Department. During the physical examination, a typical facial phenotype was observed: triangular, with a sharp chin, convergent strabismus, deep-set eyes, broad bridge and root of the nose, smooth glabella, prominent forehead, sparse hair with thin strands; low-set and dysmorphic ears (Fig. 1B). His height was 106.4 cm (-2.98 SDS), while his weight was 17.6 kg (-2.26 SDS). Bone age, determined via wrist X-ray, was 4 years and 6 months – even a greater delay of 2 years and 7 months (Fig. 1C). Despite ongoing support from a speech and language therapist, psychologist and special education teacher, the patient's language and speech development remained delayed. The child's hands and feet appeared slightly small with hypertrophy of the distal phalanges of the fingers and prominent nail plates (Fig. 1D). A slightly screaming voice can be detected during crying and laughing. From laboratory tests (CBC, biochemistry, thyroid hormones, morning and evening cortisol, electrolytes), all values were within reference range (Ta-

ble 1), only the IGF-1 concentration was 84.8 ng/mL (-1.41 SDS).

Two stimulation tests (Fig. 2) for growth hormone were performed (with arginine hydrochloride 8.8 g i.v. for 30 minutes and glucagon 0.6 mg i.m.) with opposite results. In the arginine test, the peak GH level at 60 minutes was 16.5 ng/mL (normal response), whereas in the glucagon test, the peak GH plasma concentration at 90 minutes was 5.67 ng/mL (insufficient response).

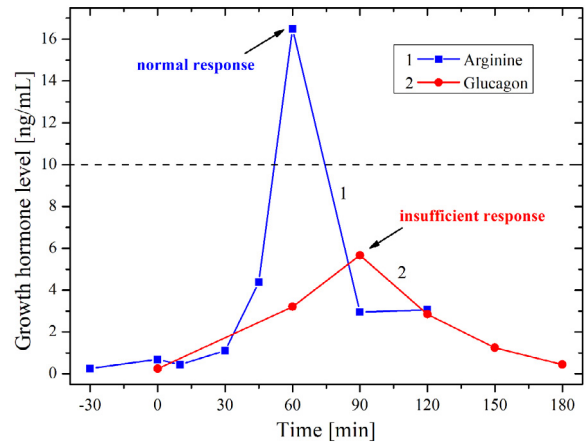


Fig. 2. Plasma concentration of growth hormone (ng/mL) over the time (min) during the stimulation tests with arginine hydrochloride (blue curve 1) and glucagon (red curve 2), the results are discordant: normal response in the arginine test (with peak GH value over 10.0 ng/mL) and insufficient response in the glucagon test (peak GH level below 10.0 ng/mL)

Therefore, MRI of the hypothalamus-pituitary were performed, revealing mild hypoplasia of the pituitary gland – a height of ≈4.6 mm (norm 6 mm), without any hypointense areas suspected for adenomas. Considering the short stature, combined with significant bone age delay, the dysmorphic facies as well as the speech and language delay, the decision for whole-exome sequencing (WES), using the next-generation sequencing (NGS) platform NovoSeq6000/Illumina, was undertaken. The results disclosed a heterozygous pathogenic variant c.7330C>T (pArg2444Ter) in exon 34 of the SRCAP gene on short arm of chromosome 16. This is the most common pathogenic variant in SRCAP gene in the literature and along with the typical clinical presentation confirmed the diagnosis Floating-Harbor syndrome (FHS). The pathogenic variant emerges de novo like in the majority of the already described cases (Fig. 1e). Considering the short stature, notable delayed bone age, as well as the MRI finding and the results from the glucagon stimulation test, a treatment with 0.033 mg/kg/day (0.65 mg/day) of recombinant human growth hormone (rhGH) subcutaneously in the evening was initiated at the age of 7 years and 10 months. At the time of preparation of

the manuscript, the child has been under this treatment for 6 months and has increased his height by 3.3 cm and gained weight by 3 kg (Table 2). The dose of the rhGH has been increased to 0.035 mg/kg/day (0.80 mg/day) s.c. During ophthalmologic evaluation, visual acuity was 0.3 in the right eye (VOD) and 0.3 in the left eye (VOS). Fundoscopy revealed normal findings in both eyes. The optic discs appeared vital with clear margins; retinal vessels and retina showed no abnormalities. Abdominal ultrasonography showed no abnormalities.

Table 2. Dynamics of patient's height, weight, IGF-1 levels and bone age^a

Calendar age (years months)	Height		Weight		IGF-1 levels before application		Bone age (years months)
	(cm)	(SDS)	(kg)	(SDS)	(ng/mL)	(SDS)	
3y 2m	83.5	-3.54	11.0	-2.79	-	-	-
4y 5m	91.5	-3.07	12.6	-2.88	118.0	-0.08	2y 6m
5y*	96.0	-2.74	14.0	-2.42	-	-	-
6y*	102.5	-2.54	15.7	-2.31	-	-	-
7y 1m	106.4	-2.98	17.6	-2.26	84.8	-1.41	4y 6m
7y 9m	109.2	-3.14	19.5	-1.91	188	+0.23	5y 2m
8y 3m	112.5	-2.99	22.5	-1.11	208	+0.52	5y 10m

* * – these values are given from the patient's parent, not measured by a physician

Discussion

FHS is a rare genetic disease that is associated with a short stature (usually below the 3rd percentile), lag in the bone age (often 1–3 years compared to chronological age), triangular dysmorphic face, as well as skeleton abnormalities such as short arms and legs, brachydactyly or clinodactyly, deficit in speech and language development. FHS is a result of frameshift or nonsense mutations in exons 33 or 34 of SRCAP gene, located on the short arm of chromosome 16 (16p11.2). SRCAP gene encodes an ATPase (catalytic subunit of SNF2-Related CBP activator protein), which plays a key role in chromatin remodeling and gene expression.

Management of FHS is symptomatic and multidisciplinary, involving growth hormone therapy for the short stature, language and speech support, as well as educational and developmental support. The use of recombinant human growth hormone (rhGH) dates back from 2001, and to date, there are 35 patients in the literature with FHS treated with rhGH, showing variable responses (Table 3). The typical dosage of rhGH is in the range of 0.025–0.060 mg/kg/day (most commonly 0.030–0.035 mg/kg/day). No clear correlation can be established between rhGH dose and final height, since the response to the treatment is highly individual. Most published cases report marked bone age delays, though the magnitude of delay varies widely. The duration of the treatment is also different in the reported patients, but almost everyone has a satisfactory response to the rhGH appli-

cation which can be concluded from the increase in the growth velocity and concentration of insulin-like growth factor-1 (IGF-1), as well as the reduction in the difference between the calendar and bone age (which is again strongly individual and not directly connected to the dose and duration of the rhGH treatment).

In contrast to the published cases of patients with FHS, who are typically small for the gestational age, our patient was born large for the gestational age which is likely attributed to the maternal diabetes type 1 which was poorly controlled during the pregnancy. Maternal hyperglycemia results in increased fetal blood glucose, leading to fetal hyperinsulinemia and consequently increased growth. Another unusual finding in this case was the inconsistency of growth hormone stimulation test results – a normal response to the arginine test, and insufficient response to the glucagon test). As a result, an MRI of the hypothalamus-pituitary gland was performed to confirm GH deficiency.

In our patient, the growth velocity is 3.3 cm for the 6 months of rhGH treatment (6.6 cm/year), which is 44.1% higher than the speed velocity from patient's 3rd to 7th year (4.58 cm/year). The bone age at the start of the treatment was 5 years and 2 months (the difference (ΔA) between bone age (BA) and calendar age (CA): $\Delta A = BA - CA$ is minus (-) 2 years and 8 months), while this difference 6 months later is (-) 2 years and 6 months. The level of IGF-1 is an important marker whose levels must be monitored before and after the start of the rhGH treatment. Low level of IGF-1 combined with a pathological response to GH stimulation tests (such as arginine, clonidine, glucagon, etc.) are laboratory indicators for GH deficiency and initiation of substitution therapy. When IGF-1 concentration remains at the lower range during the rhGH treatment, the dosage must be elevated and if IGF-1 concentration remained low despite the dose increase, then IGF-1 resistance can be the reason. In case of elevated IGF-1 levels, the dosage must be reduced in order to prevent the onset of side effects.

Monitoring patients undergoing rhGH therapy requires clinical examinations approximately every 6 months to assess height, weight, and bone age. Additionally, IGF-1 levels, lipid profile (total cholesterol, LDL, HDL), glucose and glycated hemoglobin levels (HbA_{1c}), thyroid status (TSH, fT4), and blood pressure should also be monitored. Regular ophthalmological examinations (including visual acuity assessment and fundoscopy) are also recommended. In the present case, there were no changes in these parameters within 6 months of therapy (Table 1), nor did the patient have any subjective complaints about the treatment. The IGF-1 concentration on the 6th month after the initiation of rhGH treatment is 208.0 ng/mL (0.52 SDS), still well below the targeted around + 2.0 SDS and along with the suboptimal growth velocity (6.6 cm/year), still significant bone age delay

Table 3. Characteristics of patients with FHS treated with rhGH*

Dosage of rhGH (mg/kg/day)	Age at rhGH treatment start (years months)	Height at rhGH treatment start		Bone age rhGH treatment start (years months)	ΔA	Duration of rhGH application (months)	Height at the time of report		Bone age at the time of report (years months)	ΔA	IGF-1 levels before application		IGF-1 levels at the time of report		Reference
		(cm)	(SDS)				(cm)	(SDS)			(ng/mL)	(SDS)	(ng/mL)	(SDS)	
1	0.040	5y 3m	77.0	-3.00	remarkably delayed	3y 7m	129.0	-1.90	7y 9m	-1y 1m	-	-	-	-	5
2	0.030	9y 1m	113.9	-2.90	5y 5m -3y 8m	1y 6m	130.2	-1.90	8y 4m	-2y 3m	138	-0.60	395	+1.70	6
3	0.030	10y 1m	126.2	-2.23	9y 10m -0y 3m	7y 4m	156.1	-1.20	-	-	99.8	-1.57	-	-	7
4	-	7y	-	-	-	6m	115.0	-4.32	-	-	-	-	-	-	8
5	-	4y	-	-	-	7y	129.0	-2.84	-	-	-	-	-	-	8
6	-	5y	-	-	-	2y	106.9	-2.90	-	-	-	-	-	-	8
7	-	10y	-	-	-	2y	154.5	-2.95	-	-	-	-	-	-	8
8	-	4y	-	-	-	12y	155.0	-2.89	-	-	-	-	-	-	8
9	-	5y	-	-	-	6y	117.0	-4.00	-	-	-	-	-	-	8
10	-	5y	-	-	-	3y	123.0	-0.90	-	-	-	-	-	-	8
11	0.035	5y 4m	99.0	-3.84	3y 0m -2y 4m	2y 3m	112.5	-2.22	8y 0m	+0y 5m	-	-	-	-	9
12	0.025-0.050	3y 5m	85.0	-3.11	2y 0m -1y 5m	5y 1m	116.4	-2.40	concordant with CA	68.0	-0.48	-	+1.0	-	10
13	-	3y	-	-2.50	delayed	3y 0m	-	-2.00	-	-	-	-	-	-	11
14	-	5y	-	-3.20	delayed	9y 0m	154.0	-1.80	-	-	-	-	-	-	11
15	-	5y 4m	-	-3.40	delayed	-	-	-1.70	-	-	-	-	-	-	11
16	0.033	10y	107.8	-4.90	5y 0m -5y 0m	2y	137.0	-3.60	12y 0m	0	-	-	-	-	12
17	0.050	5y 2m	92.5	-4.52	3y 5m -1y 10m	1y	98.0	-4.40	-	-	-	-	-	-	13
18	0.057	2y	74.7	-3.62	0y 9m -1y 3m	0y 1m	-	-	-	-	-	-	49.2	-0.70	13
19	0.057	4y 10m	92.3	-4.12	2y 9m -2y 1m	4y 2m	120.5	-2.56	-	-	-	-	-	-	13
20	0.025	5y	93.8	-3.84	2y 6m -2y 6m	1y 7m	103.4	-3.49	-	-	-	-	163.0	+0.64	13
21	0.067	6y 6m	95.0	-5.30	2y 6m -4y 0m	4y 3m	119.0	-3.86	-	-	-	-	343.0	+0.96	13
22	0.050	5y 2m	92.7	-4.47	delayed	4y 3m	118.0	-3.31	-	-	-	-	141.0	-1.01	13
23	0.050	1y 5m	68.5	-4.17	delayed	2y 2m	88.6	-2.96	-	-	-	-	56.5	-0.84	13
24	0.042	2y 3m	75.0	-4.17	1y 1m -1y 2m	0y 3m	77.9	-3.81	-	-	-	-	86.5	+0.37	13
25	0.050	4y 11m	-	-3.10	2y 10m -2y 1m	8y 1m	-	-1.10	-	-	-	+0.3	-	+1.7	14
26	0.050	4y 3m	-	-3.40	3y 1m -1y 2m	2y 9m	-	-2.60	-	-	-	+1.6	-	+3.3	14
27	0.050	7y 11m	-	-3.00	3y 7m -4y 4m	2y 6m	-	-2.00	-	-	-	+2.1	-	+2.6	14
28	0.050	10y 5m	-	-2.10	9y 4m -1y 1m	4y 2m	-	-2.50	-	-	-	+4.2	-	+3.9	14
29	0.050	8y	112.8	-3.33	delayed	4y 7m	141.3	-2.70	concordant with CA	223.1	-0.52	-	-	-	15
30	0.043	6y 9m	100.0	-4.50	3y 9m -3y 0m	0y 6m	106.3	-3.69	-	-	95.9	-1.15	257.0	+1.35	16
31	0.033	3y 6m	81.0	-3.60	1y 3m -2y 3m	0y 6m	83.5	-4.11	-	-	108.0	+0.60	-	-	17
32	0.030-0.035	4y 5m	86.0	-4.11	1y 3m -3y 2m	11y 10m	150.2	-3.28	concordant with CA	-	-	-	540.0	+1.0	2
33	0.030	2y 2m	78.2	-3.40	1y 3m -0y 11m	3y 8m	104.0	-2.76	2y 11m	-2y 11m	-	-	-	-	18
34	0.045-0.060	4y	83.4	-4.63	delayed	9y 4m	141.9	-2.50	-	-	55.3	-1.02	-	-	19
35	0.040	2y 1m	73.0	-4.79	1y 0m -1y 1m	3y 2m	100.0	-	-	-	172.0	+1.74	-	-	20
36	0.033-0.035	7y 9m	109.2	-3.14	5y 2m -2y 8m	0y 6m	112.5	-2.99	5y 10m	-2y 6m	188.0	+0.23	208.0	+0.52	present case

* ΔA – difference between bone and calendar age (ΔA=BA-CA)

($\Delta A = -2$ years and 6 months) and the lack of any significant side effects from the rhGH treatment, a decision to slightly increase in the dose of rhGH is made: from 0.033 mg/kg/day (0.65 mg/day) to 0.035 mg/kg/day (0.80 mg/day) s.c. The patient will continue to be monitored every 6 months while being on rhGH treatment.

Patient perspective

The family expressed gratitude for reaching a definitive diagnosis and for the initiation of rhGH therapy. Since the beginning of the replacement therapy and with the help of the speech and language therapist, the physical and mental development of their child have improved noticeably. The patient feels better which makes the parents calmer. They report no difficulties with the therapy and acknowledge the importance of the regular follow-up.

Conclusion

FHS is a rare disorder, which must be considered in children presenting with proportional short stature, dysmorphic facial features (including a triangular face shape, deep-set eyes, and a prominent nose) and marked speech and language delay. In the presence of this classical clinical triad for FHS, target sequencing of the SRCAP gene can be suggested as the first-line molecular diagnostic test. In cases with atypical or incomplete clinical manifestations, a broader next-generation sequencing (NGS) panel must be considered, including SRCAP and other genes associated with short stature, language delay, and facial dysmorphism such as CREBBP, EP300, KMT2D, KDM6A, NIPBL, SMC1A, SMC3 and others, in order to differentiate FHS from other syndromes (such as Rubinstein-Taybi syndrome, Cornelia de Lange syndrome, Kabuki syndrome, and others).

Management of patients with FHS involves a multidisciplinary team consisting of endocrinologists, geneticists and developmental specialists. In cases with confirmed growth hormone deficiency, therapy with recombinant human growth hormone (rhGH) is indicated, typically at a dose between 0.030-0.040 mg/kg/day, with close monitoring of insulin-like growth factor-1 (IGF-1) levels both prior and during treatment.

Acknowledgements

We are thankful to the patient and his family for allowance to publish this case.

Declarations

Funding

The authors declare that the study received no funding.

Author contributions

Conceptualization, T.T.P.; Writing – Original Draft Preparation, T.T.P.; Writing – Review & Editing, T.T.P. and N.Y.Y.; Visualization, T.T.P.; Supervision, N.Y.Y.

Conflicts of interest

Both authors declare that there is no potential conflict of interest.

Data availability

All data during this study are included in this published article.

Ethics approval

The study was conducted following the regulations of the Hospital and Medical University – Sofia, as well as General Data Protection Regulation (GDPR). Written informed consent was obtained from the parent of the patient for publication of this article and any accompanying images.

References

- Patton MA, Hurst J, Donnai D, McKeown CM, Cole T, Goodship J. Floating-Harbor syndrome. *J Med Genet.* 1991;28(3):201. doi:10.1136/jmg.28.3.201
- Turkunova ME, Barbitoff YA, Serebryakova EA, et al. Molecular Genetics and Pathogenesis of the Floating Harbor Syndrome: Case Report of Long-Term Growth Hormone Treatment and a Literature Review. *Front Genet.* 2022;13:846101. doi:10.3389/fgene.2022.846101
- Lacombe D, Patton MA, Elleau C, Battin J. Floating-Harbor syndrome: description of a further patient, review of the literature, and suggestion of autosomal dominant inheritance. *Eur J Pediatr.* 1995;154(8):658-661. doi:10.1007/BF02079072
- Nikkel SM, Dauber A, De Munnik S, et al. The phenotype of Floating-Harbor syndrome: clinical characterization of 52 individuals with mutations in exon 34 of SRCAP. *Orphanet J Rare Dis.* 2013;8:63. doi:10.1186/1750-1172-8-63
- Wieczorek D, Wüsthof A, Harms E, Meinecke P. Floating-Harbor syndrome in two unrelated girls: mild short stature in one patient and effective growth hormone therapy in the other. *Am J Med Genet.* 2001;104(1):47-52. doi:10.1002/ajmg.1585
- Cannavò S, Bartolone L, Lapa D, et al. Abnormalities of GH secretion in a young girl with Floating-Harbor syndrome. *J Endocrinol Invest.* 2002;25(1):58-64. doi:10.1007/BF03343962
- Stagi S, Galluzzi F, Bindi G, et al. Precocious puberty in a girl with Floating-Harbor syndrome. *J Pediatr Endocrinol Metab.* 2007;20(12):1333-1338. doi:10.1515/JPEM.2007.20.12.1333
- White SM, Morgan A, Da Costa A, et al. The phenotype of Floating-Harbor syndrome in 10 patients. *Am J Med Genet A.* 2010;152(4):821-829. doi:10.1002/ajmg.a.33294
- Galli-Tsinopoulou A, Kyrgios I, Emmanouilidou E, et al. Growth hormone deficiency: an unusual presentation of Floating-Harbor syndrome. *Hormones (Athens).* 2011;10(3):236-240. doi:10.14310/horm.2002.1314

10. García RJ, Kant SG, Wit JM, Mericq V. Clinical and genetic characteristics and effects of long-term growth hormone therapy in a girl with Floating-Harbor syndrome. *J Pediatr Endocrinol Metab.* 2012;25(1-2):207-212. doi:10.1515/jpem.2011.406
11. Seifert W, Meinecke P, Krüger G, et al. Expanded spectrum of exon 33 and 34 mutations in SRCAP and follow-up in patients with Floating-Harbor syndrome. *BMC Med Genet.* 2014;15:127. doi:10.1186/s12881-014-0127-0
12. Nagasaki K, Asami T, Sato H, et al. Long-term follow-up study for a patient with Floating-Harbor syndrome due to a hotspot SRCAP mutation. *Am J Med Genet A.* 2014;164(3):731-735. doi:10.1002/ajmg.a.36314
13. Zhang S, Chen S, Qin H, et al. Novel genotypes and phenotypes among Chinese patients with Floating-Harbor syndrome. *Orphanet J Rare Dis.* 2019;14(1):144. doi:10.1186/s13023-019-1111-8
14. Homma TK, Freire BL, Honjo R, et al. Growth and clinical characteristics of children with Floating-Harbor syndrome: analysis of current original data and a review of the literature. *Horm Res Paediatr.* 2020;92(2):115-123. doi:10.1159/000503782
15. Son HW, Lee JE, Oh SH, Keum C, Chung WY. Effects of long-term growth hormone therapy in a girl with Floating-Harbor syndrome. *Ann Pediatr Endocrinol Metab.* 2020;25(2):126-131. doi:10.6065/apem.1938144.072
16. Bo H, Jiang L, Zheng J, Sun J. Floating-Harbor Syndrome treated with recombinant human growth hormone: a case report and literature review. *Front Pediatr.* 2021;9:747353. doi:10.3389/fped.2021.747353
17. Prosvirnina A, Bolmasova A, Melikyan M. A case of a Floating-Harbor syndrome in a child with severe short stature. *Horm Res Paediatr.* 2021;94(1):343.
18. Yang YC, Tang Q, Yan LJ, et al. A case of Floating-Harbor Syndrome with “growth and language development delay” as its clinical manifestation. *Pharmacogenomics Pers Med.* 2023;16:1091-1096. doi:10.2147/PGPM.S433444
19. Jeon J, Noh ES, Hwang IT. Floating-Harbor Syndrome in a Korean patient with short stature and early puberty: a case report. *J Clin Res Pediatr Endocrinol.* 2024. doi:10.4274/jcrpe.galenos.2024.2023-12-12
20. He Q, Deng Y, Xu L, et al. Recombinant human growth hormone treatment of Floating-Harbor syndrome: a case report and literature review. *BMC Pediatr.* 2025;25:97. doi:10.1186/s12887-025-05437-7